



Tanzania Patients CCBRT

Feb 24-March 9, 2012

operated patients

G.Ulrich Exner

Peter Ickler

Luijisyo Mwakalukwa

CCBRT, Dar es Salaam

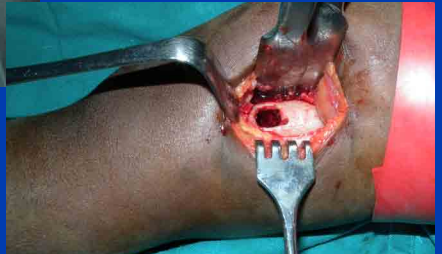
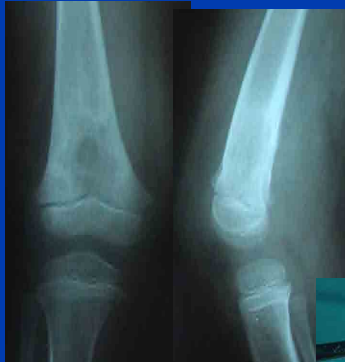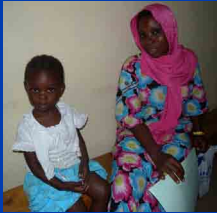Orthopaedie Zentrum Zuerich



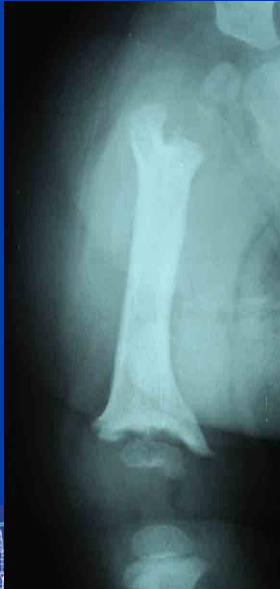**Universität
Zürich** UZH

orthopädie C
zentrum Z
zürich Z

Acute osteomyelitis refused to be treated during weekend!!

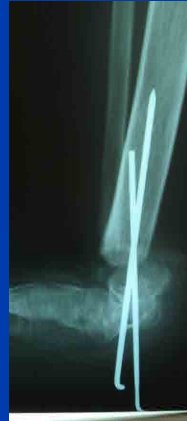
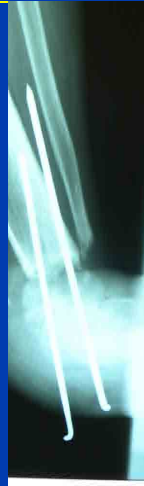
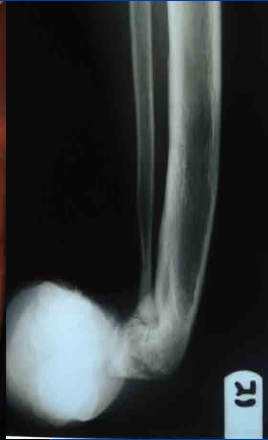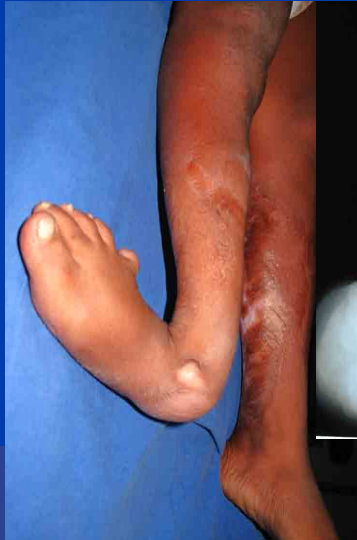**But I did it finally on Saturday.
Why?**

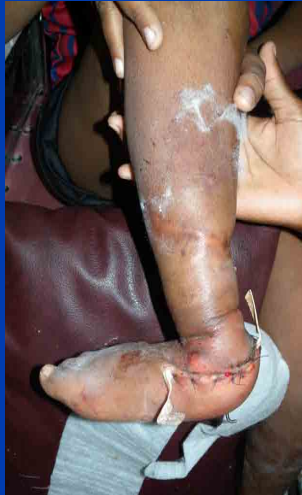

**To avoid
this!!**

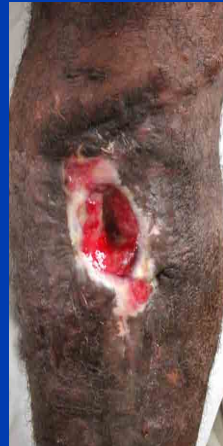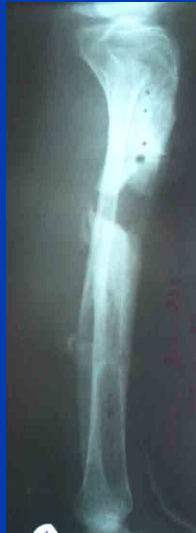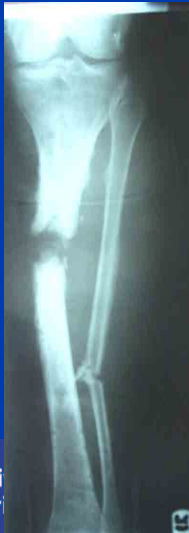Foot dislocation following overroll trauma



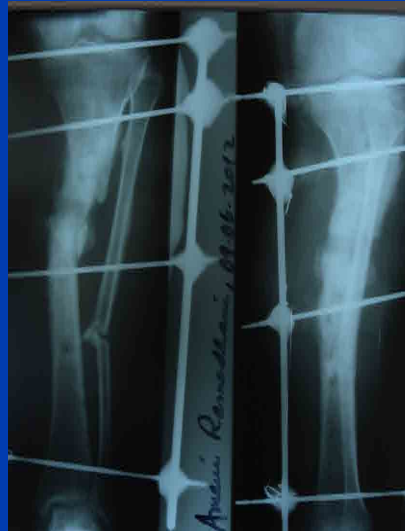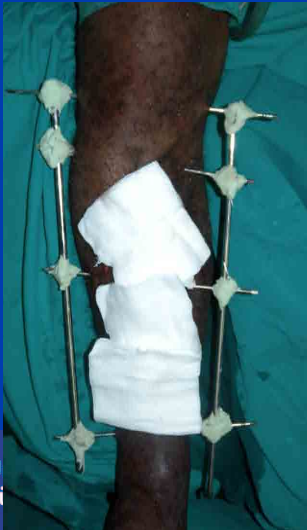Axial position of planta pedis for full weight bearing orthosis



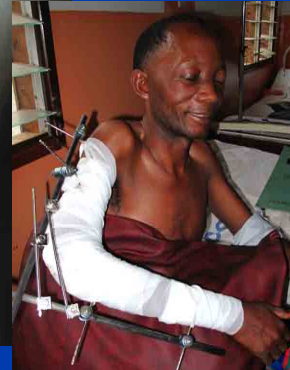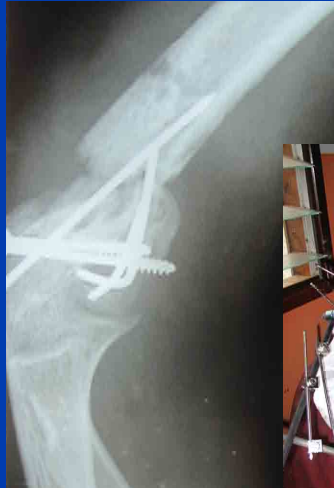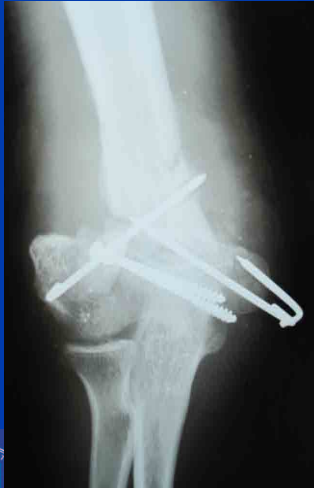Infectious pseudarthrosis



Debridement, cement spacer improvised external fixation, will need: medial gastrocnemius flap , Masquelet technique

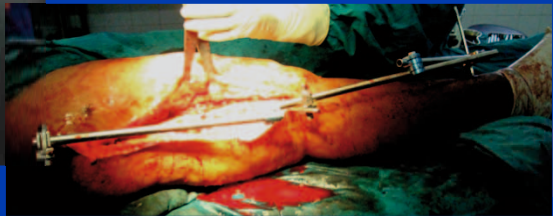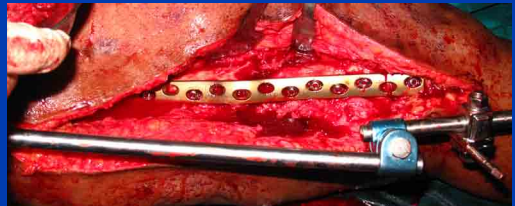

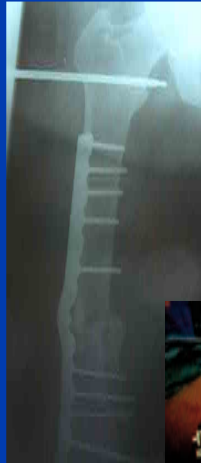
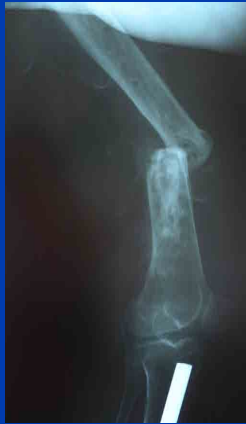Fracture with added implants. Infection. Fully debrided- cement. External fixation

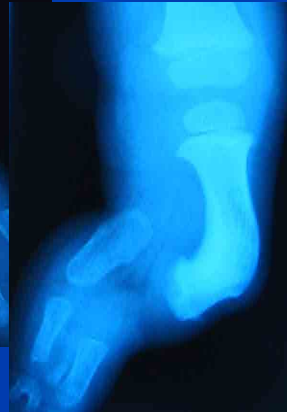
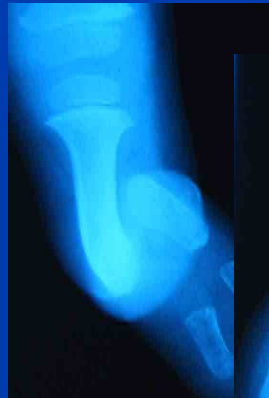
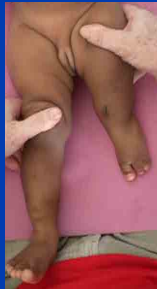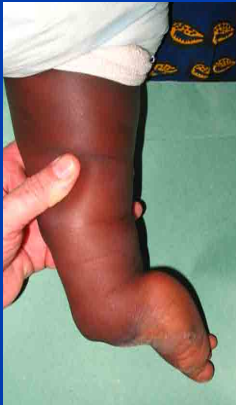Femoral pseudarthrosis 2006 presented to me already 2011

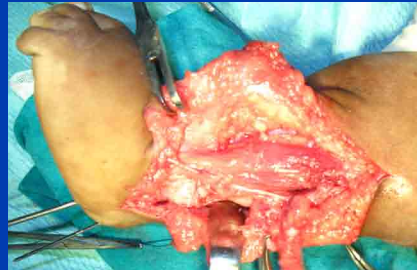
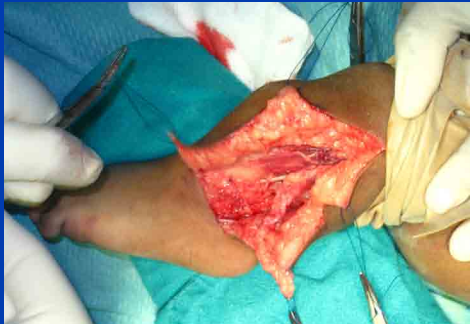
welded plate – femorotibial fixator because of
knee stiffnes. Posterior iliac crest bone graft



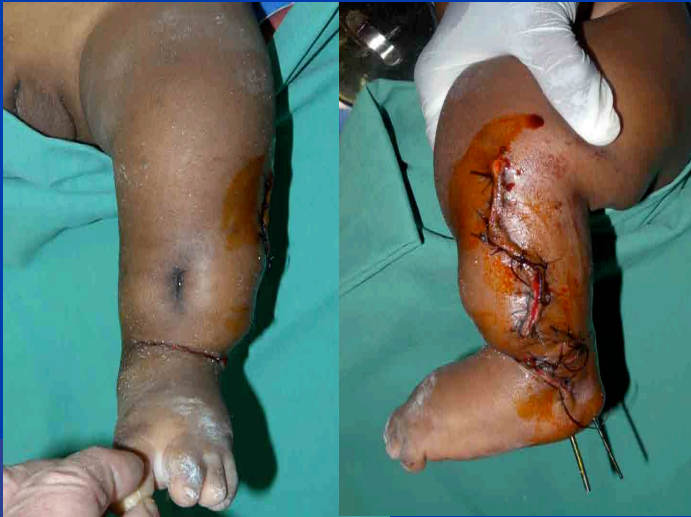Fibular Hemimelia Exner technique



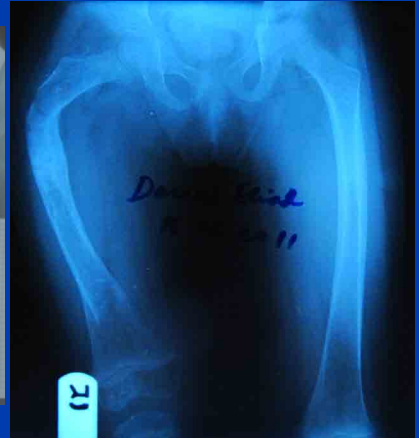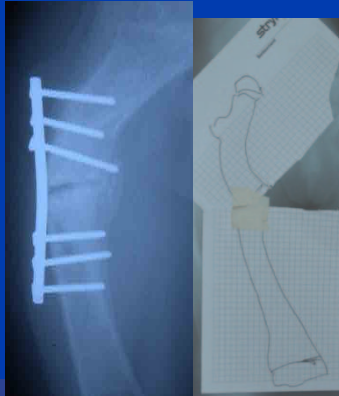
Distal metaphyseal ,Pemberton‘ with wedge from tibia osteotomy. K-wire, cast



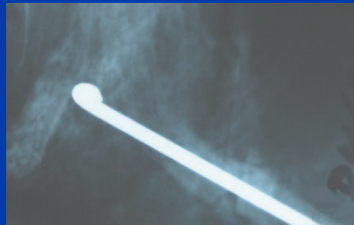
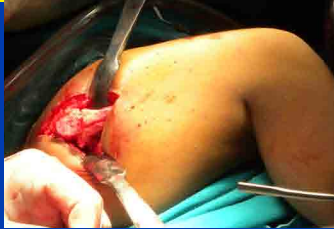1 week postoperative



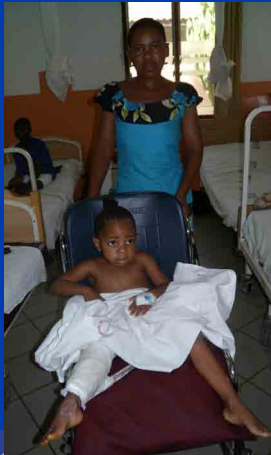
Osteogenesis imperfecta



Retro-antero-grade nailing with Rush-pin, spica cast



Osteogenesis imperfecta cont.



Prof. C. Gerber: All people make mistakes; idiots always the same ones, intelligent people new ones. You decide to what group you want to belong.

I wanted to plate this fracture. From the drawings I realized that I must have treated this girl one year ago with a plate.

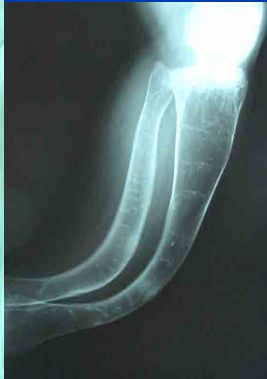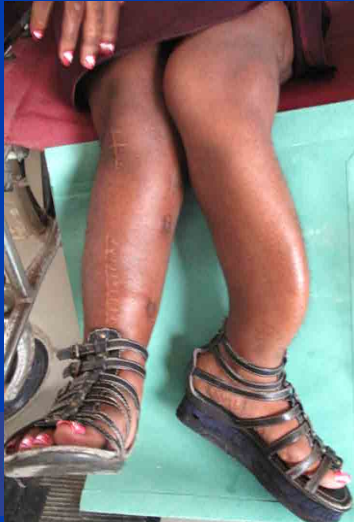So I decided to make at least not the same again and therefore the fracture was opened, resection for shortening and reduction, retrograde careful blunt drilling with increasing size Rush pins, then anterograde nailing from trochanteric region.

Spica cast.

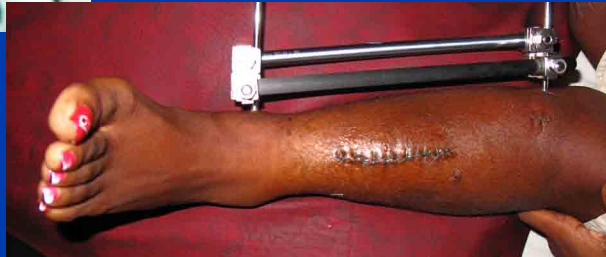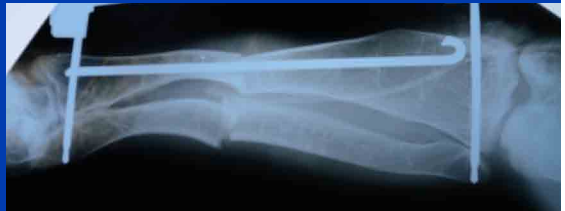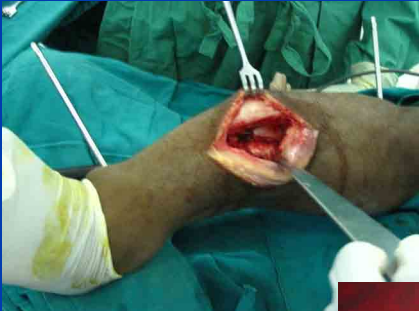GUE

Osteogenesis imperfecta

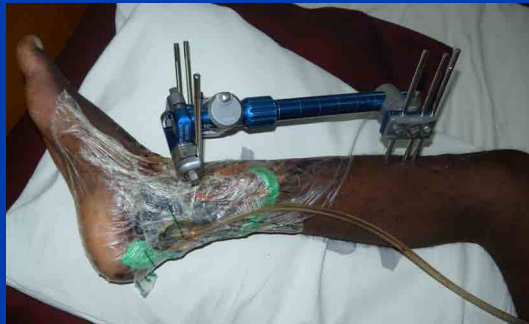Any surgery without plan is planless



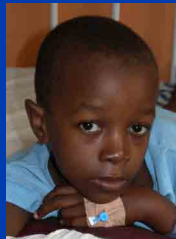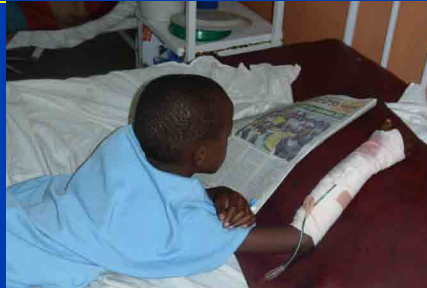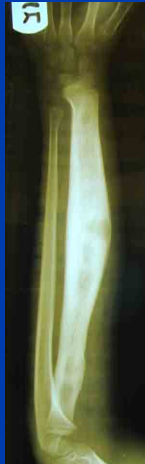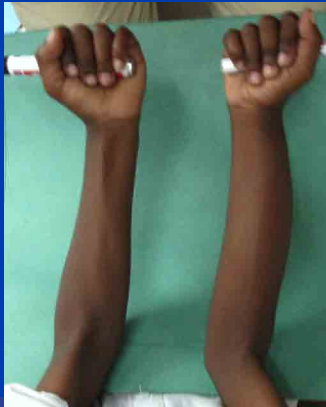
The exception: crossing pins only in metaphyses



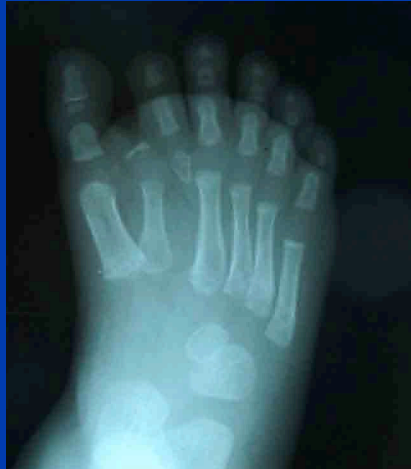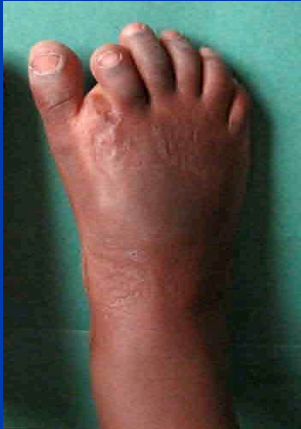VAC system for infection



Chronic osteomyelitis. Henry approach for complete sauerisation

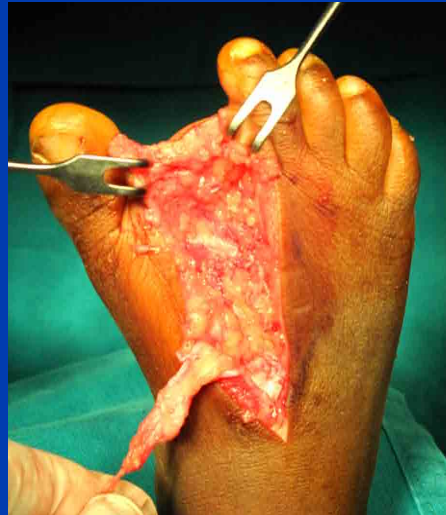
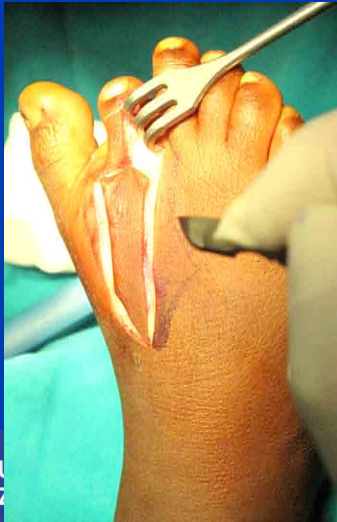
Polydactylism. 'A little removed before'

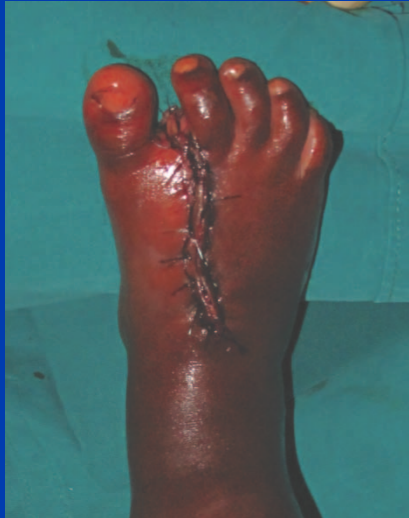

Complete ray resection.

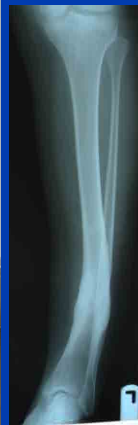
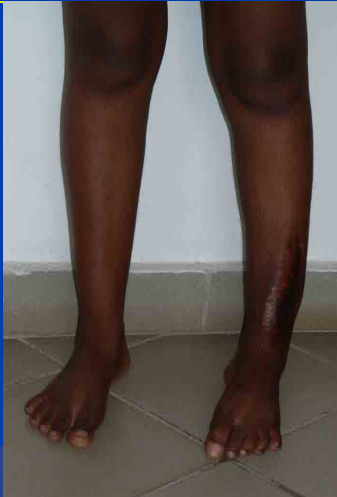Tendon harvested for intermetatarsal ligament stabilisation



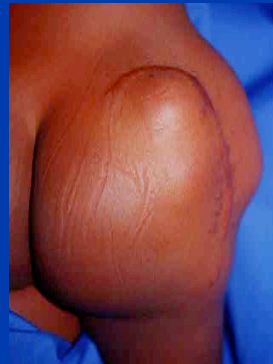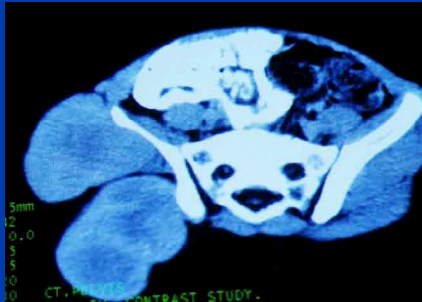Final reconstruction



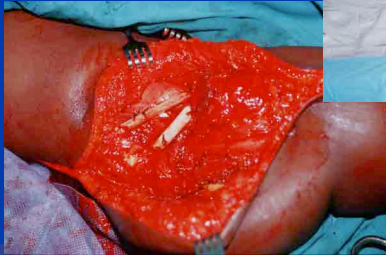
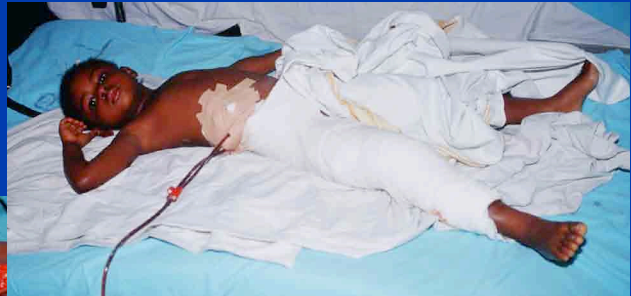Varus following foot injury. No f/u X-Ray



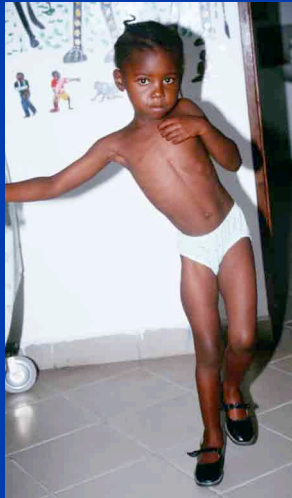
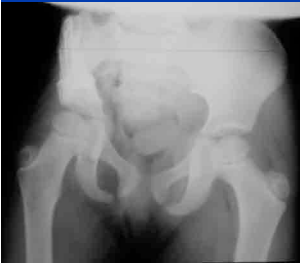Follow up: Desmoid 2002



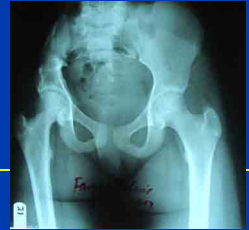postoperative



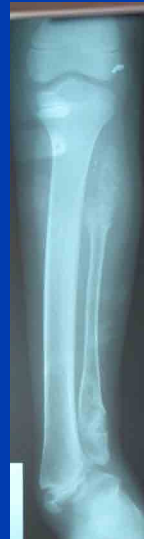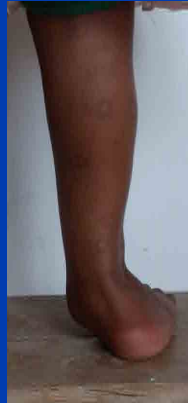2004



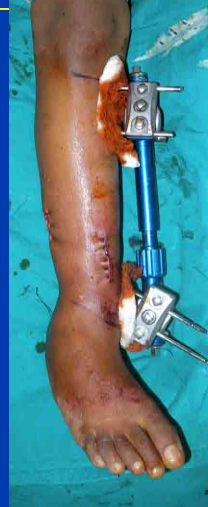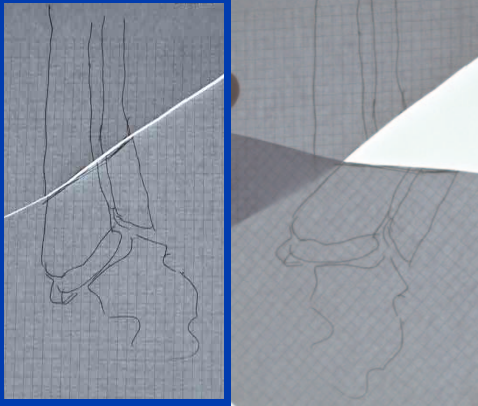
2012



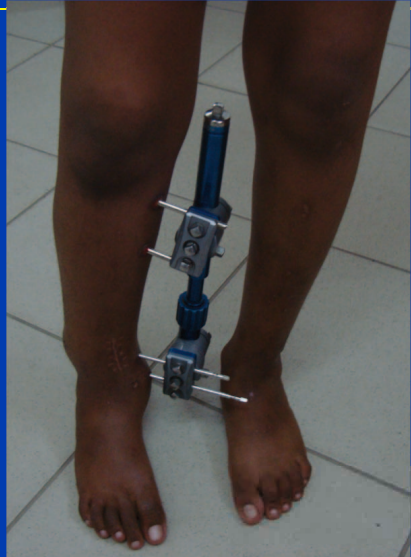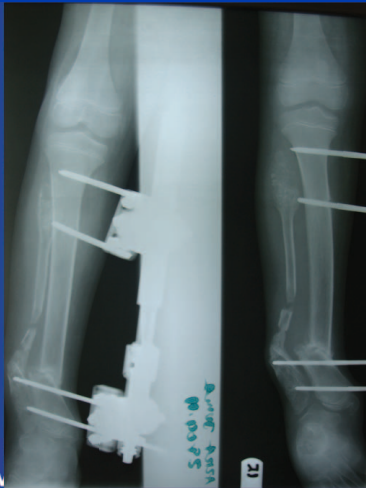Valgus short fibula osteochondroma



The plan



Correction achieved



Home visit Arusha. ,my future Daktari‘



Thank you for:

- Allowing me to work at this place
- Collaborate with excellent Doctors, Nurses and all other People needed (Administration, Kitchen, Cleaning ...) to achieve this for our children – our future
- Patience, when I shout – I shout only against my insufficiency

Assante sana protect your children and your country

